

# **Side Effects of Orthodontic Treatment**

**Dr. Jamilian**

**<https://jamilian.net>**

## **INTRA ORAL RISKS**

- Enamel demineralization
- Enamel trauma
- Enamel wear
- Pulpal reaction
- Root resorption
- Periodontal problem
- Allergy trauma

## **EXTRA ORAL RISKS**

- Allergy
- Trauma
- Burns
- Temporomandibular disorder (TMD)

## **SYSTEMIC RISKS**

- Cross infection
- Infective endocarditis

The complications associated with orthodontic treatment are a result of multifactorial process with :

- 1.The patient
- 2.The orthodontist
- 3.The orthodontic appliances
- 4.The orthodontic procedure

## **INTRA ORAL RISKS**

**The most important aspect of orthodontic care is to have an extremely high standard of oral hygiene before and during orthodontic treatment.**

**Arch wires, headgears and brackets may cause significant damage either during an active phase of treatment or during debanding and debonding.**

## **ENAMEL DEMINERALIZATION/CARIES/WHITE SPOT LESIONS**

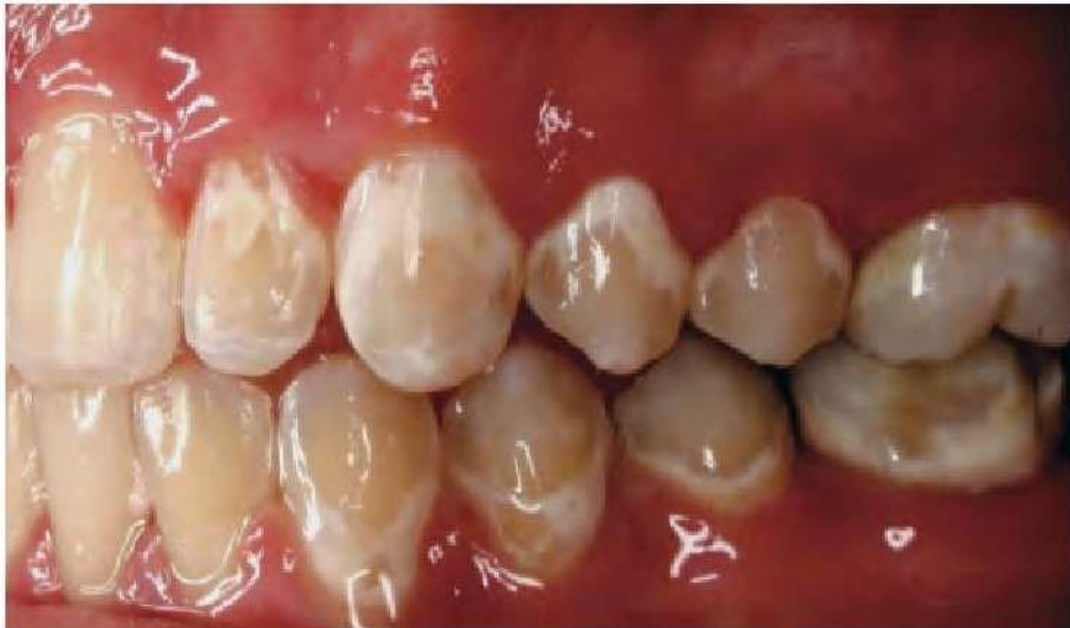- **Enamel demineralization, usually on smooth surfaces, is unfortunately a common complication in orthodontics.**
- **It is a common negative sequel of orthodontic treatment in the absence of proper oral hygiene.**
- **It is the loss of calcified tooth substance due to attack by acidic-by-product of plaque metabolism.**

## **Etiology**

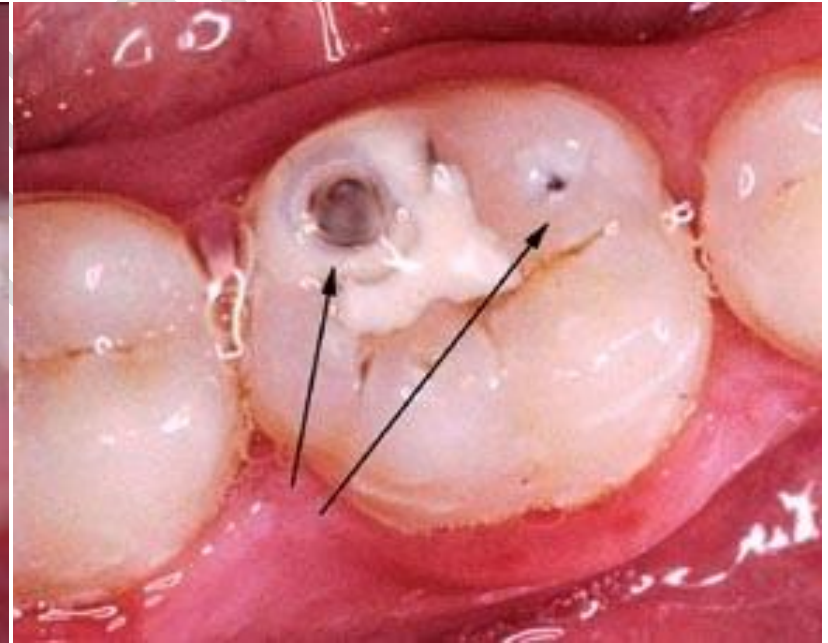
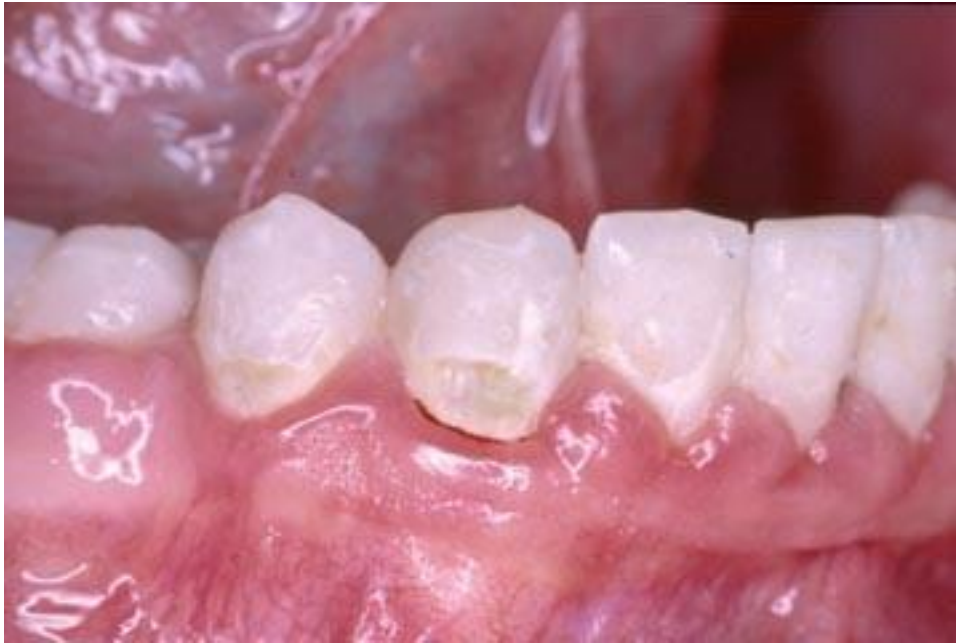- **Increase in food stagnation and increase in the retentive sites of bacteria**
- **Changes in the microflora (low PH environment)**
- **Poor oral hygiene, Diet, long treatment time and interproximal caries are the predictors for white spite lesions**

## **Incidence**

**However, any tooth in the mouth can be affected, often a number of anterior teeth show decalcification.**



**In severe cases, frank cavitation is seen which requires restorative intervention.**





## PREVENTIVE MEASURES

- Good oral hygiene is essential for successful orthodontic treatment; dietary control of sugar intake is also needed in order to minimize the risk of decalcification.
- Daily fluoride rinses or fluoride gel or varnish may prevent and reduce decalcifications. Use of fluoride throughout treatment can prevent white spot formation surprisingly.
- Other fluoride release mechanisms include fluoride releasing bonding agents, elastic ligatures containing fluoride, cement containing fluoride.

- Care is needed during debanding and debonding
- There is the potential for enamel damage especially with ceramic brackets
- No use of chlorohexidine mouthwashes during orthodontic treatment due to discoloration of teeth
- Select small brackets
- Complete coverage of enamel with cement while banding
- Minimal use of looped arch wires

## **TREATMENT PROCEDURE**

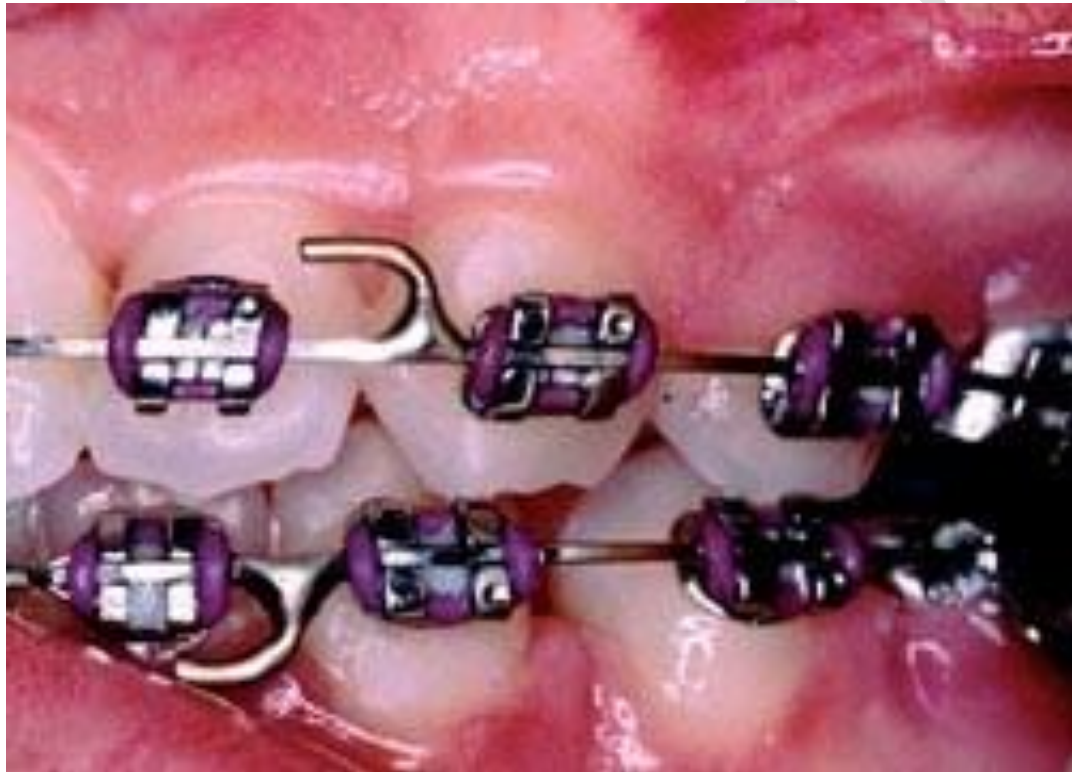**Where demineralization is present post treatment, fluoride application either via toothpaste, or by adjunct fluoride mouthwash (0.05% sodium fluoride daily rinse or 0.2% sodium fluoride weekly rinse), can be helpful in demineralizing the lesion and reducing the unsightliness of the decalcification. The amount of white spot is reduced 25% by fluoride rinse**

## ENAMEL TRAUMA

- **When placing appliances careless use of a band seater can result in enamel fracture.**
- **Care is required when large restorations are present since these can result in fracture of unsupported cusps.**
- **Debonding can also result in enamel fracture, both with metal and ceramic brackets.**

## **ENAMEL WEAR**

- **Wear of enamel against both metal and ceramic brackets (abrasion) may occur.**
- **It is common on upper canine tips during retraction as the cusp tip hits the lower canine brackets.**
- **Ceramic brackets are very abrasive and therefore contraindicated for the lower anterior teeth where there is any possibility of the brackets occluding with the upper teeth.**
- **Carbonated drinks and pure juices are the commonest causes of erosion and should be avoided in patients with fixed appliances.**



Upper canine tip showing abrasion from the lower canine metal bracket

## Pulpal Reaction

- **Some degree of pulpitis is expected with orthodontic tooth movement which is usually reversible or transient.**
- **Rarely it leads to loss of vitality, but there may be an increase in pulpitis in previously traumatized teeth with fixed appliances.**
- **Light forces are advocated with traumatized teeth as well as baseline monitoring of vitality which should be repeated three monthly.**

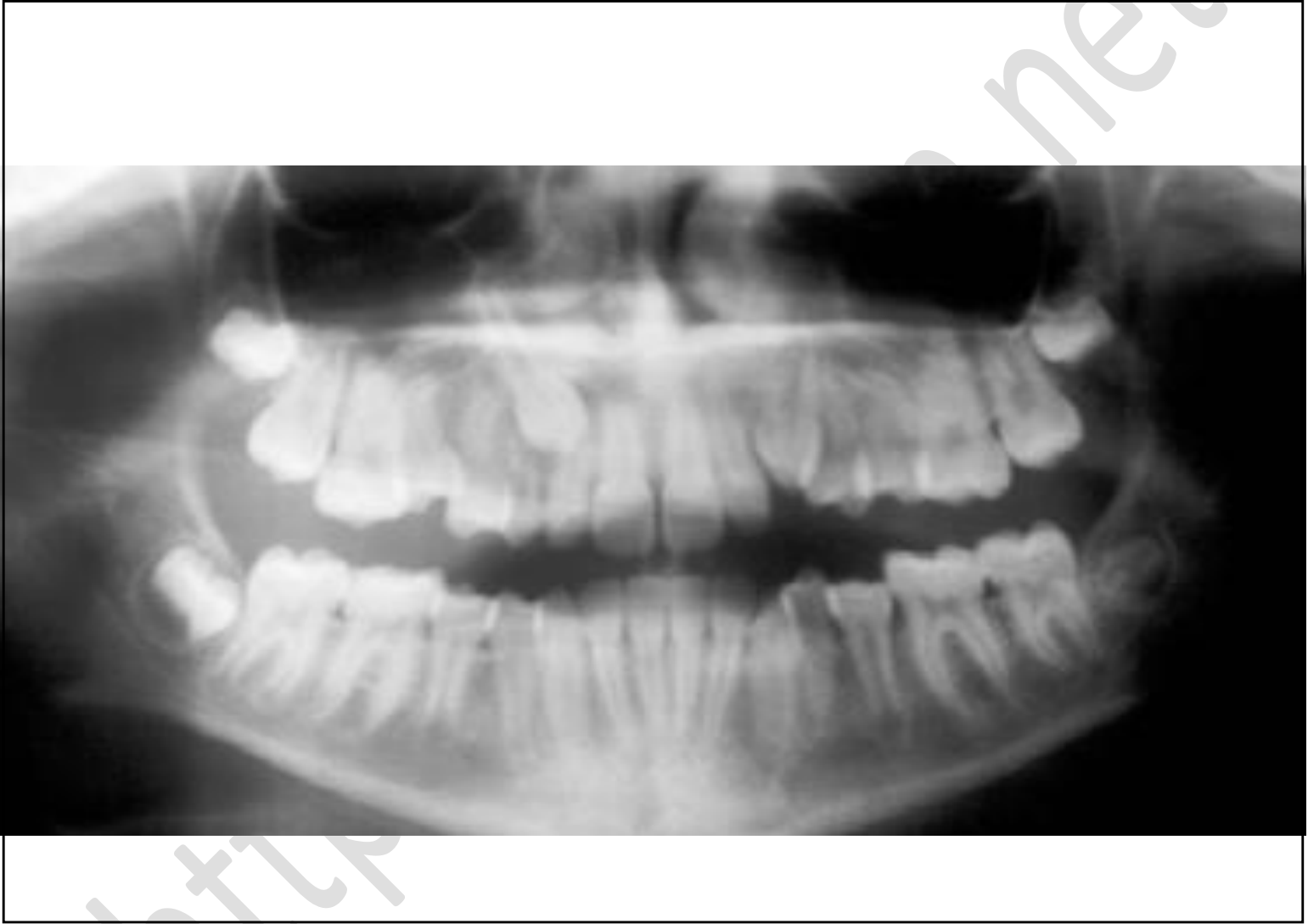## ROOT RESORPTION

- **Some degree of external root resorption is inevitably associated with fixed appliance treatment, although the extent is unpredictable.**
- **Resorption may occur on the apical and lateral surface of the roots**





<https://jamilian.net>

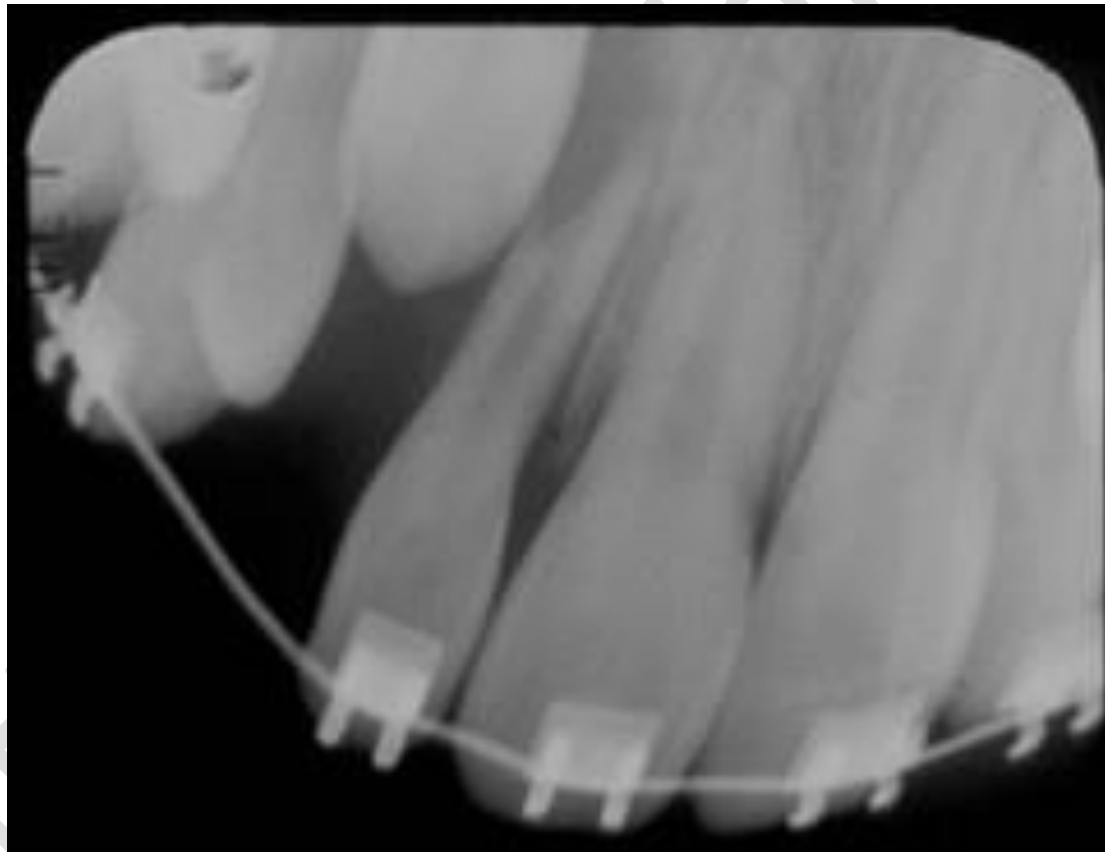


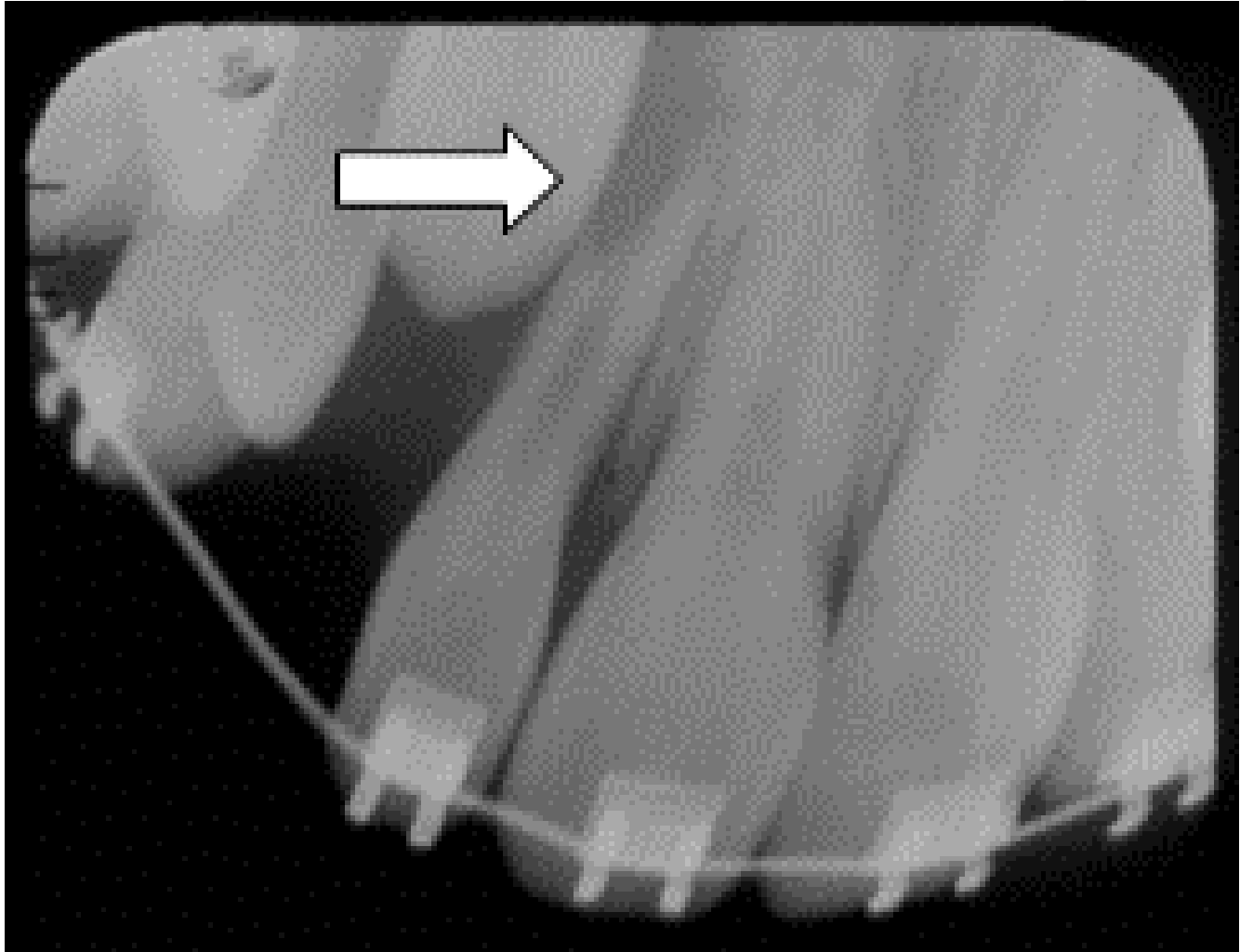
## **RISK FACTORS OF ROOT RESORPTION**

- The mechanism of tooth resorption is unclear.
- Root resorption is multifactorial, the risk factors which are associated with cases with root resorption are:
  - Blunt shaped and short roots show a greater amount of resorption than other root forms.
  - History of traumatized teeth, have an increased risk of further resorption.
  - Non vital teeth and root treated teeth have an increased risk of resorption.
  - Heavy forces are associated with resorption
  - Use of rectangular wires
  - The distance a tooth is moved

- Type of orthodontic tooth movement by moving root apices against cortical bone (torque) (Tooth intrusion)
- Combined orthodontic and orthognathic procedure
- Chronological age
- Inter elastic traction
- familial risk
- Systematic diseases such as hyperthyroidism, paget's disease
- Longer treatment duration
- Fixed appliance treatment
- On average 1–2 mm of apical root is lost during a course of orthodontic treatment

**Treatment of impacted canines may induce resorption of the adjacent teeth because of the length of treatment time and the distance the canine is moved.**





http

## Management of root resorption

Obtain initial records including x-ray

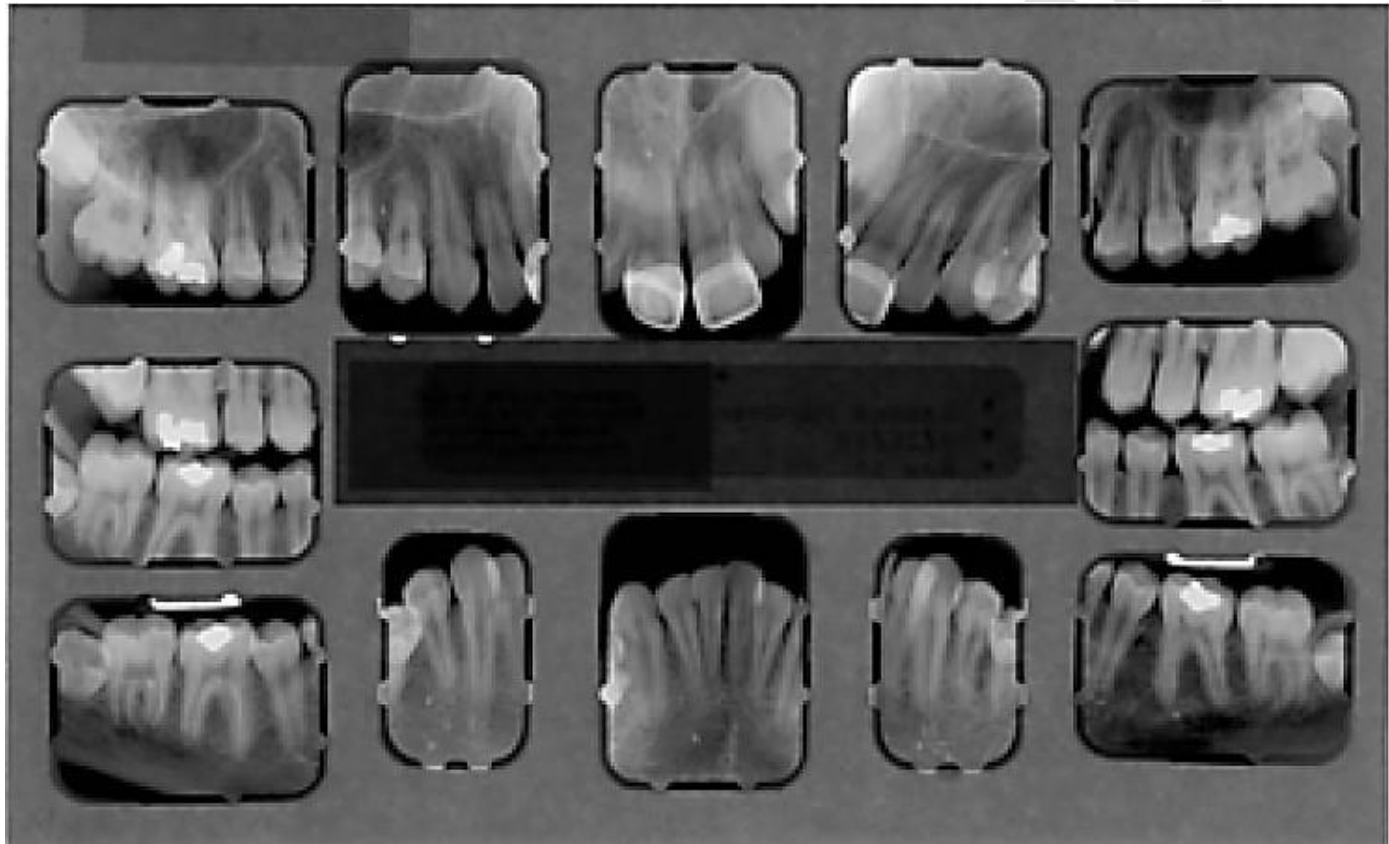
Use caution in moving abnormally shaped tooth

Orthodontic forces should be intermittent, light and well distributed

Follow up x-rays

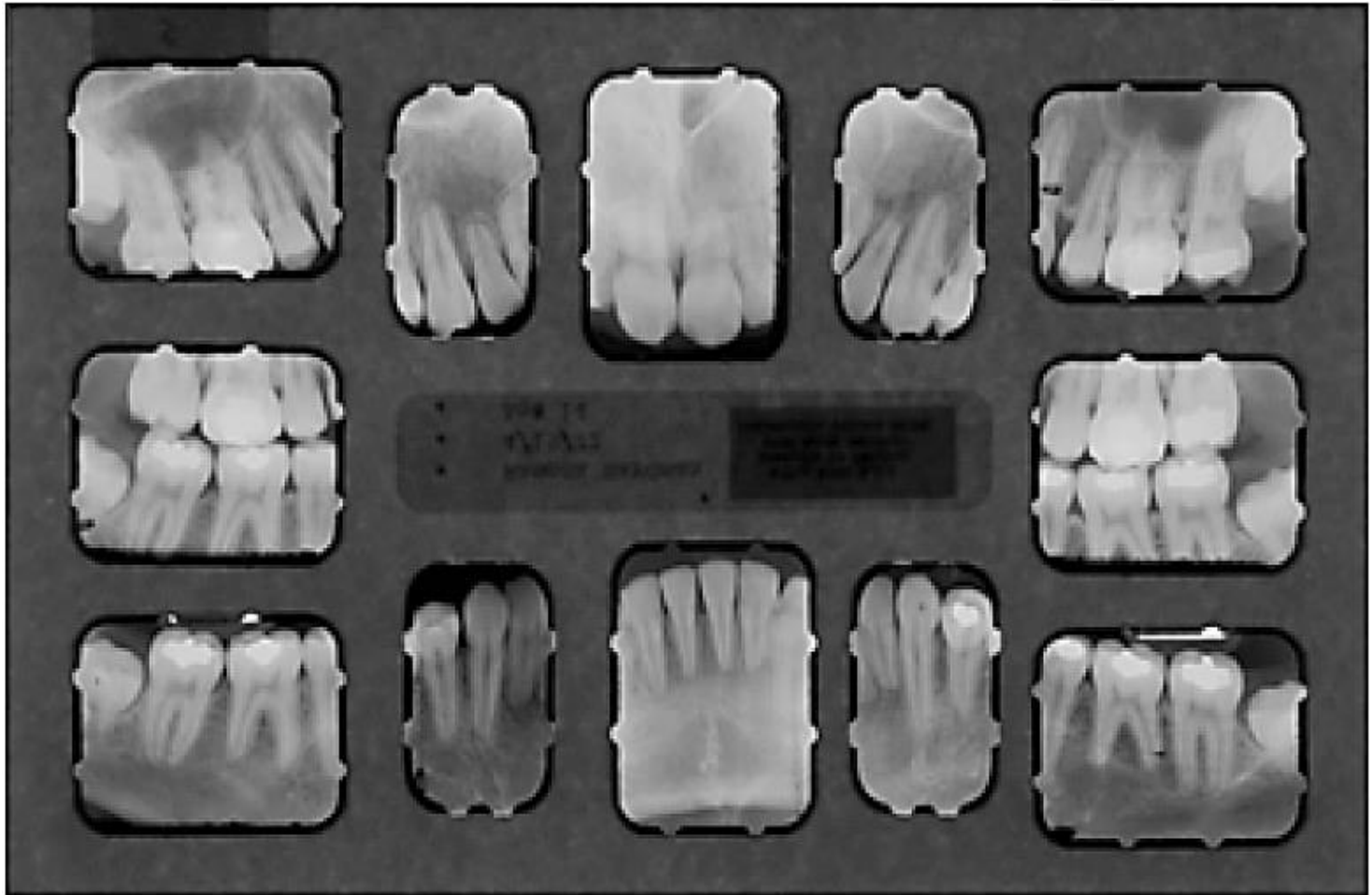
Debonding

Endodontic treatment and splinting

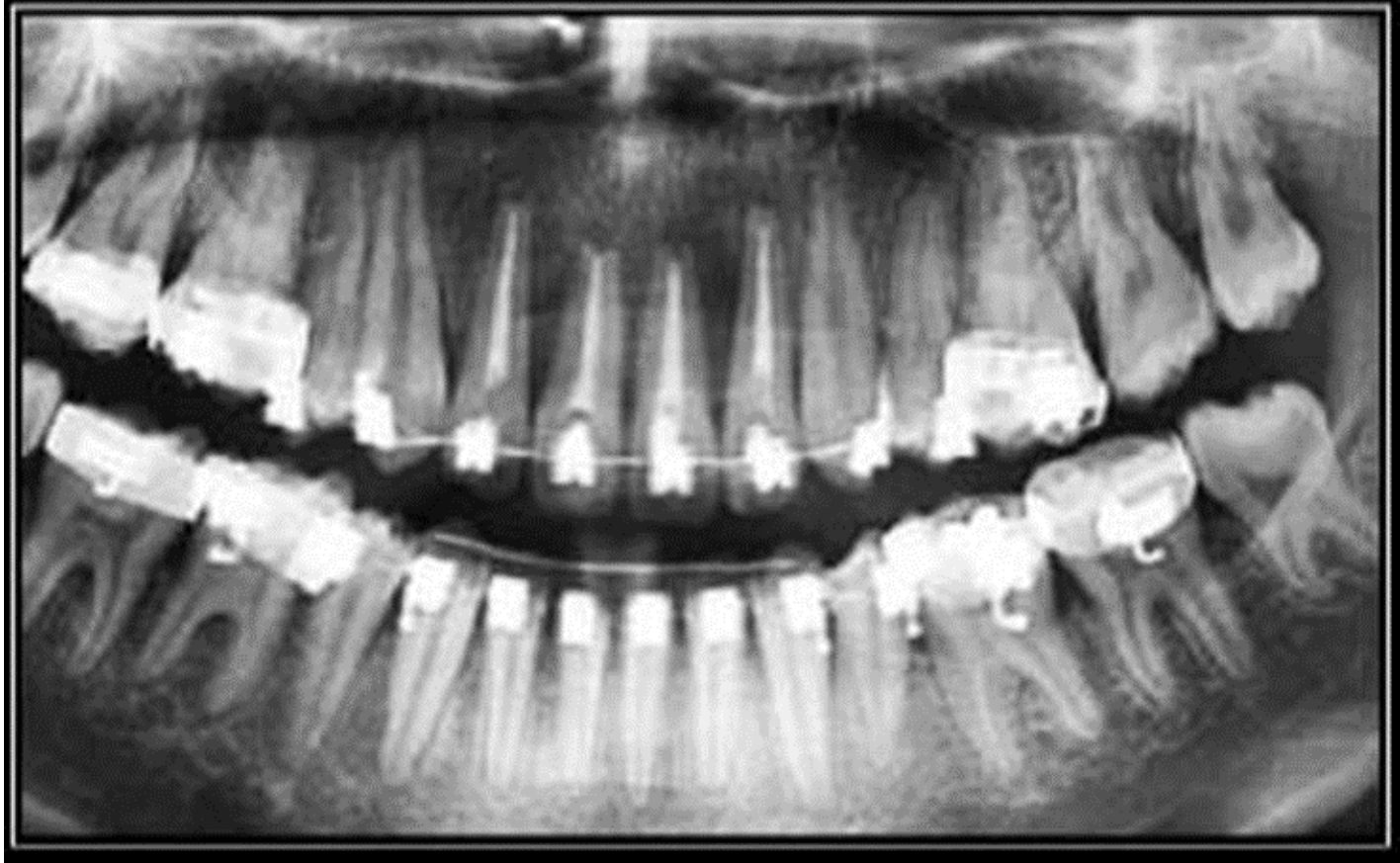


Pre-orthodontic treatment full-mouth radiographs



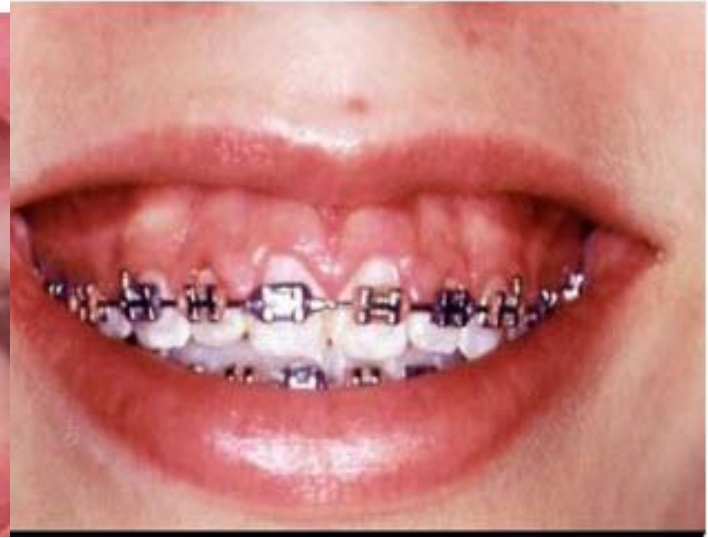
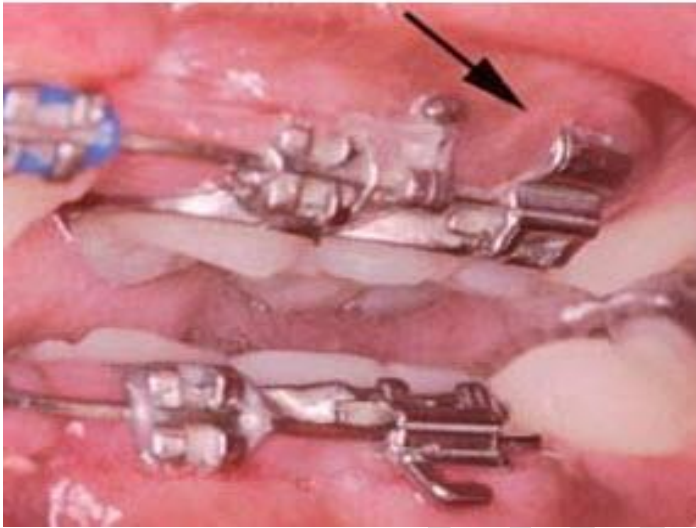


Post-orthodontic treatment full-mouth radiographs demonstrating root resorption



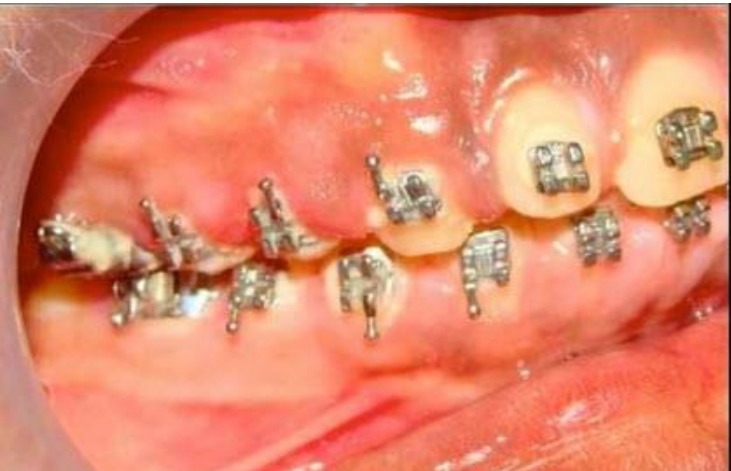## PERIODONTAL PROBLEM

- **Fixed appliances make oral hygiene difficult even for the most motivated patients, and almost all patients experience some gingival inflammation.**
- **Resolution of inflammation usually occurs a few weeks after debond,**
- **Bands cause more gingival inflammation than bonds, which is not surprising since the margins of bands are often seated subgingivally.**



<https://jan...>

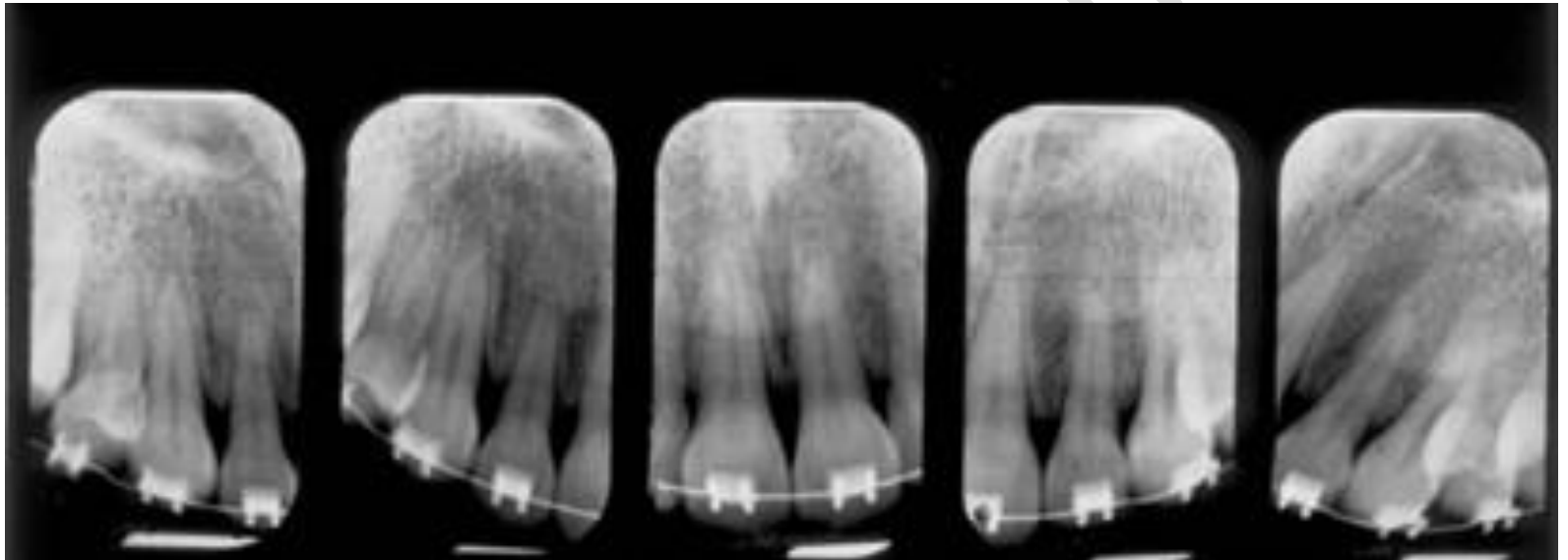
st



<https://jamninet.com>

## **TREATMENT OF PERIODONTAL**

- ✓ Oral hygiene instruction is essential in all cases of orthodontic treatment
- ✓ Use of adjuncts such as electric toothbrushes, interproximal brushes
- ✓ Use of chlorhexidine free mouthwashes, fluoride mouthwashes
- ✓ Regular professional cleaning must be emphasized



***Crestal bone loss occurring with orthodontic treatment associated with poor oral hygiene***

## Allergy

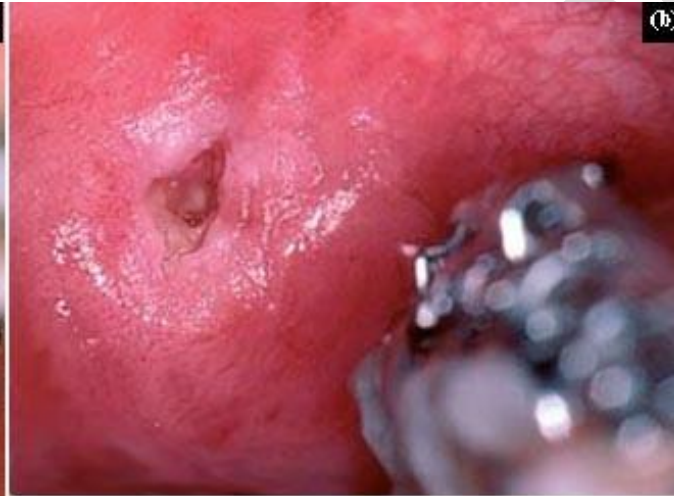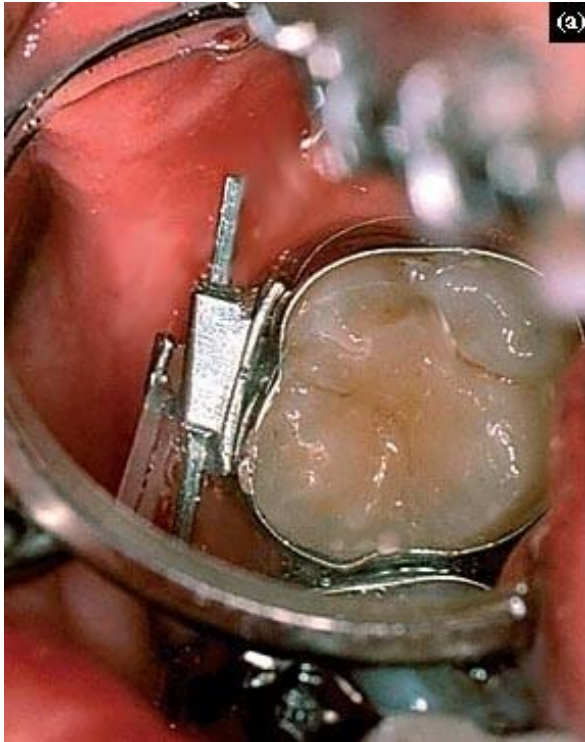
- Allergy to orthodontic components intra-orally is exceedingly rare, however, there have been studies on the nickel release and corrosion of metals with fixed appliances.
- There is a significant release of nickel and iron into the saliva of patients just after placement of fixed appliances.
- There are a few cases with severe latex allergies who may be affected by elastomeric or operators gloves.



## TRAUMA

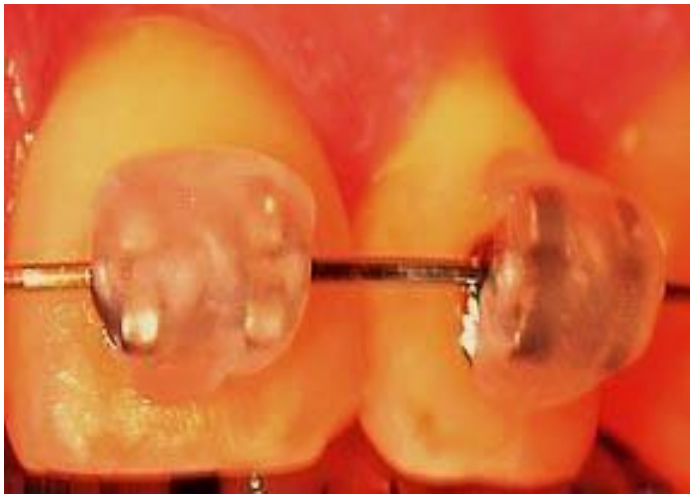
Laceration to gingiva and mucosa

Hyperplasia between treatment sessions from the arch wire and bonds, especially where long unsupported stretches of wire rest against the lips.

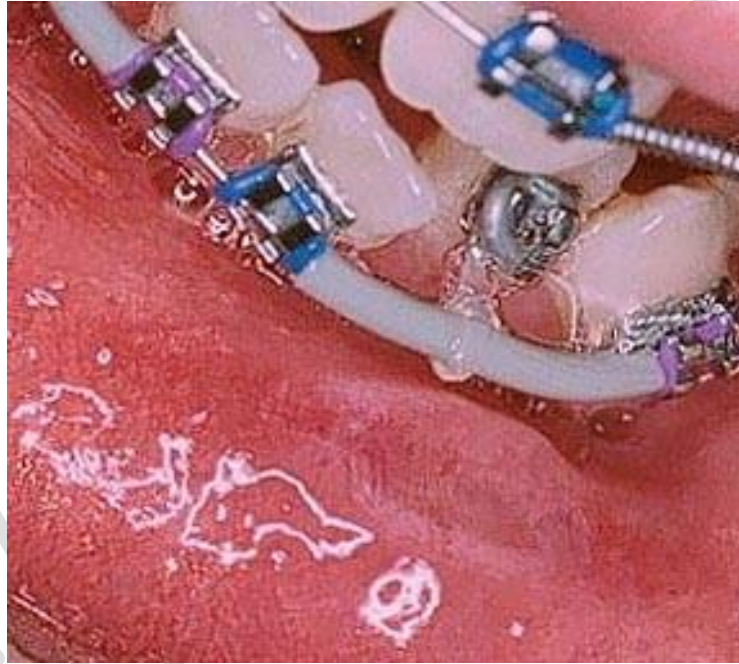


*Trauma to the cheek from an unusually long distal length of arch wire resulting in an ulcer.*

**The use of dental wax over the bracket may help to reduce trauma and discomfort, as may rubber bumper sleeving on the unsupported archwire.**



Dental wax over the bracket may help to reduce trauma and discomfort.

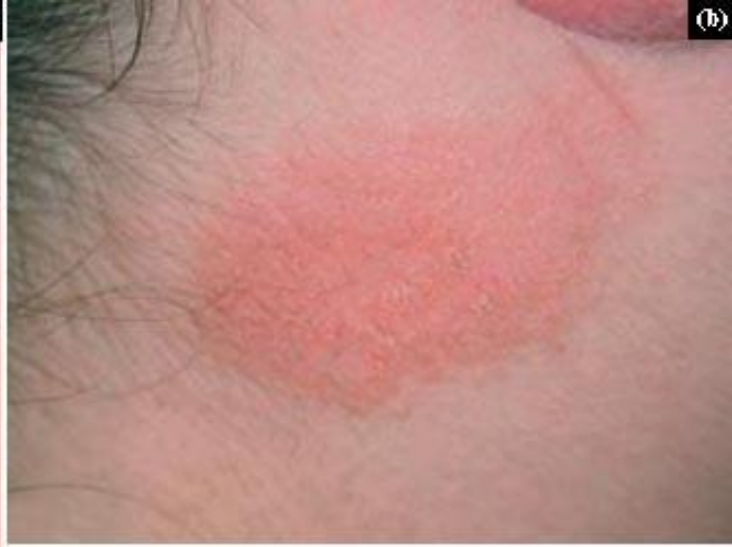
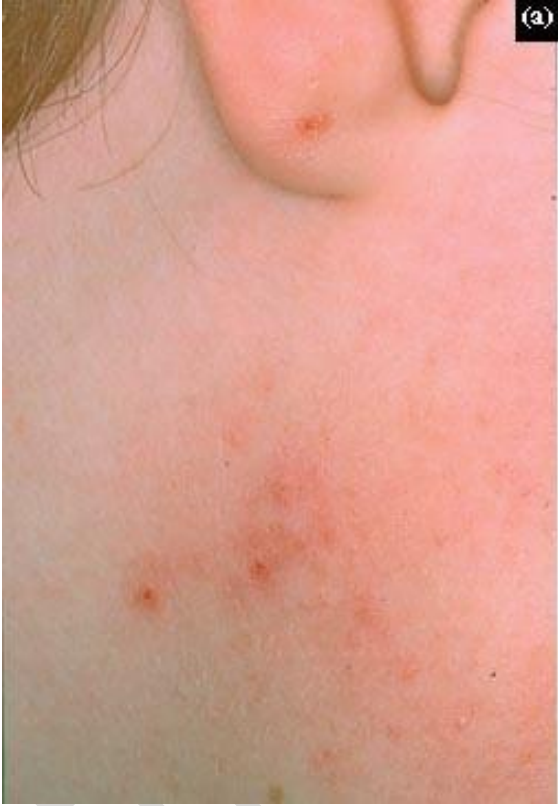
Bumper sleeve has been placed along the wire to prevent further trauma

## **EXTRA-ORAL RISKS**


### **ALLERGY**

- **Allergy to nickel is more common in extra-oral settings, most usually the headgear face bow or head strap.**
- **The use of sticking plaster over the area in contact with the skin is sufficient to relieve symptoms.**
- **Allergy to latex and bonding materials has been reported although these are rare.**



## **TRAUMA**

- **Following a well publicised case of eye trauma in a patient wearing headgear a number of safety headgear products have been designed and explicit guidelines are now available.**
- **These measures include safety bows, rigid neck straps and snap release products to prevent the bow from disengaging from the molar tubes or acting as a projectile.**
- **Every headgear and bow must incorporate a safety feature. Failure to observe safety guidelines on the use of headgear is medico-legally indefensible.**



**Safety release mechanisms on head gear**



## BURNS

- Burns, either thermal or chemical are possible both intra- and extra-orally with inadvertent use of chemicals or instruments.
- Acid etch, electro thermal debonding instruments and sterilized instruments which have not cooled down all have the potential to burn and care should be taken in their use.

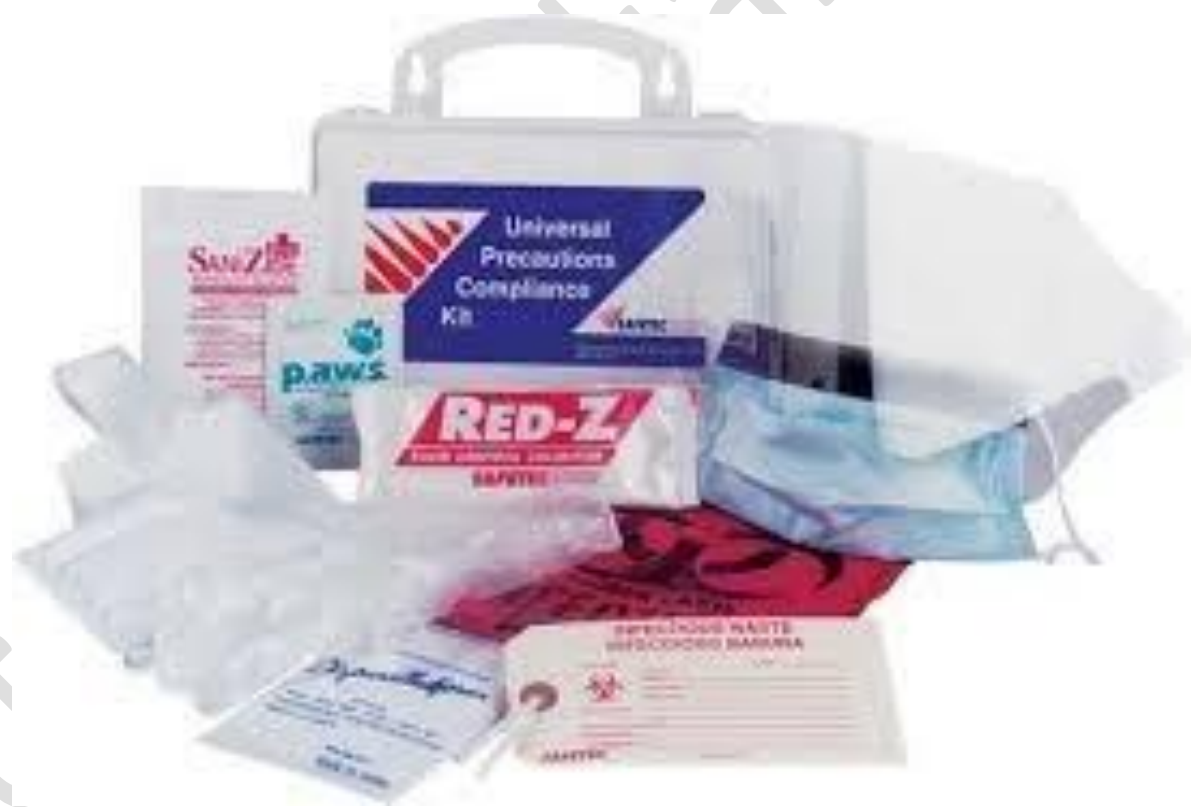## **TEMPROMANDIBULAR DYSFUNCTION (TMD)**

- **Pre-existence of TMD should be recorded, and the patient advised that treatment will not predictably improve their condition.**
- **Some patients may suffer with increased symptoms during treatment which must also be discussed at the beginning of treatment.**
- **Where patients experience symptoms during treatment, treatment should be directed at eliminating occlusal disharmony and joint noises whilst reassuring the patient.**
- **Standard treatment regimes may also be indicated e.g. soft diet, jaw exercises.**

## **SYSTEMIC RISKS**

### **CROSS INFECTION**

- **Spread of infection between patients, between operator and patient and by a third party should be prevented by cross infection procedures throughout the surgery.**
- **Use of gloves, masks, sterilized instruments and 'clean' working areas are paramount.**
- **A medical history must be taken for every patient to determine risk factors, although cross infection control should be of a standard to prevent cross contamination regardless of medical status.**



htx

ian.net

## INFECTIVE ENDOCARDITIS

- Patients at risk of endocarditis should be treated in consultation with their cardiologist and within the appropriate guidelines.
- The patient must exhibit immaculate oral hygiene, antibiotic cover will be required for invasive procedures such as extractions, separation, band placement and band removal.
- It is recommended that bonded attachments are used on all teeth to negate the need for antibiotic cover for both separator and band placement, as well as removal. This also reduces the risk of unwanted plaque stagnation areas.
- Chlorhexidine mouthwash has been advocated prior to any fixed treatment.

## Relapse

Any change from final tooth position at the end of treatment

<https://jamilian.net>

## **Causes of Relapse**

**The major causes of relapse after orthodontic treatment include**

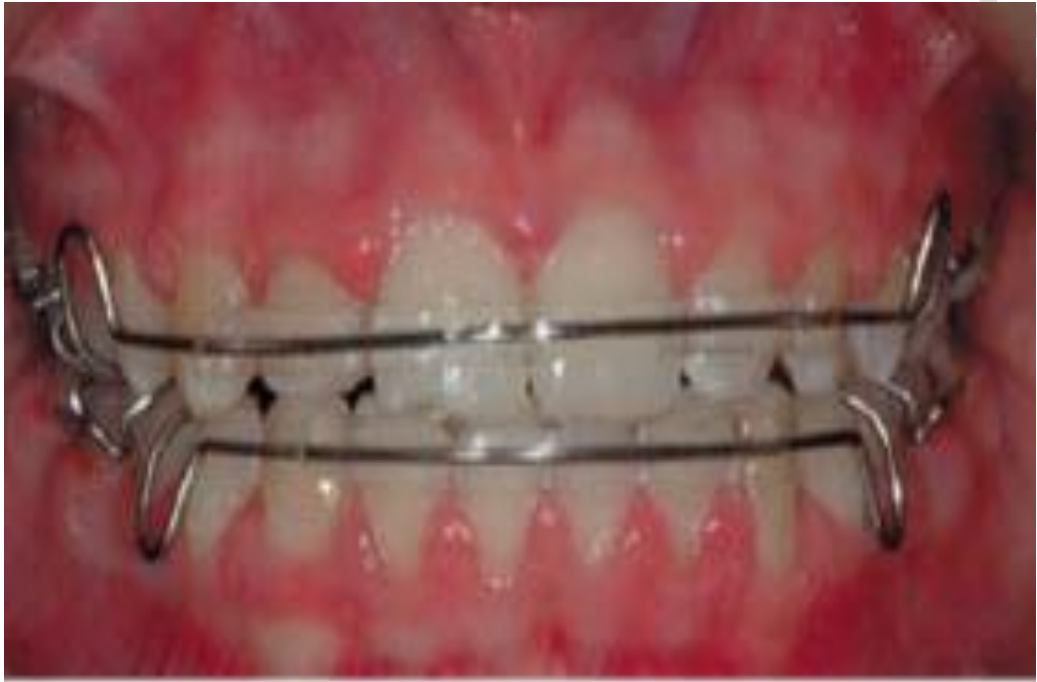- 1.The elasticity of gingival fibers before PDL reorganization has been completed.**
- 2.Cheek/lip/tongue pressures**
- 3.Jaw growth.**
- 4.Unfavorable growth is the major contributor to changes in occlusal relationships.**

## RETAINERS

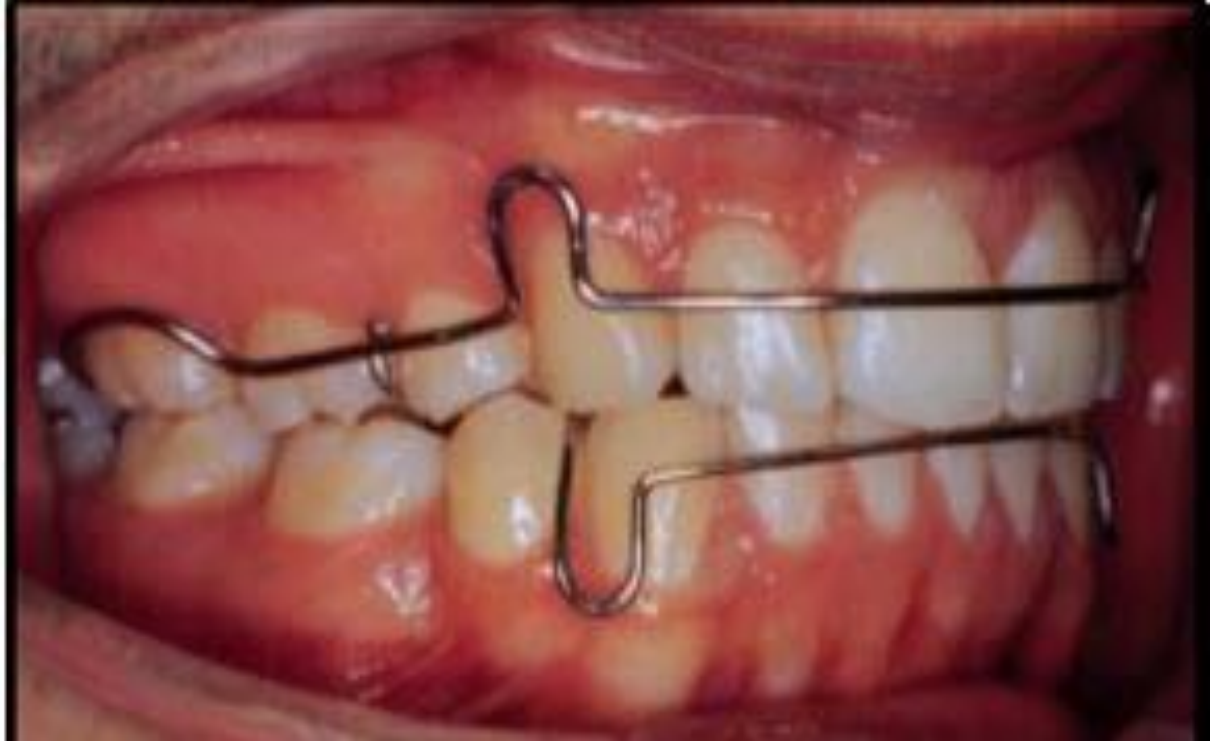
- 1- Removable Retainers
- 2- Fixed Retaine

<https://ijamilian.net>



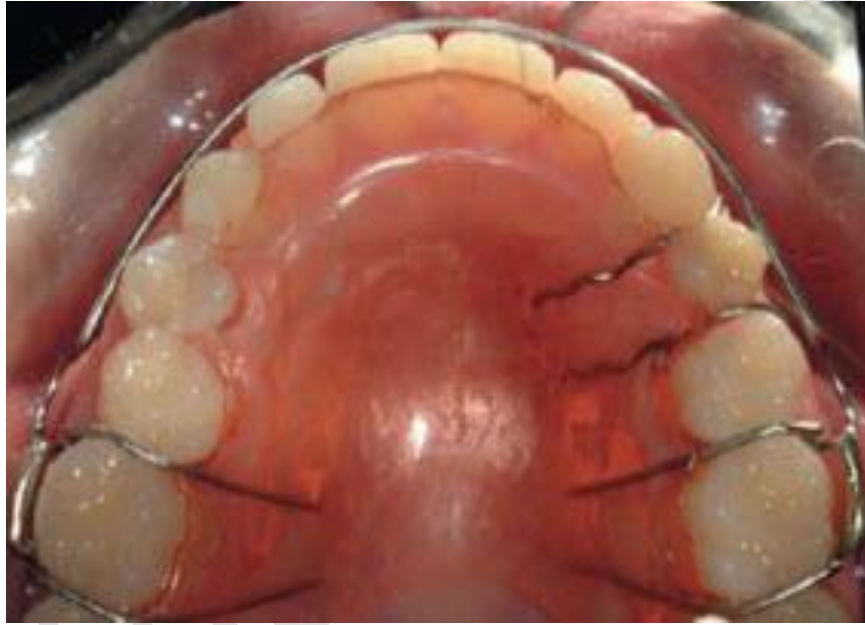

<https://www.orthodontics.com>



<http://www.dentalnet.com>

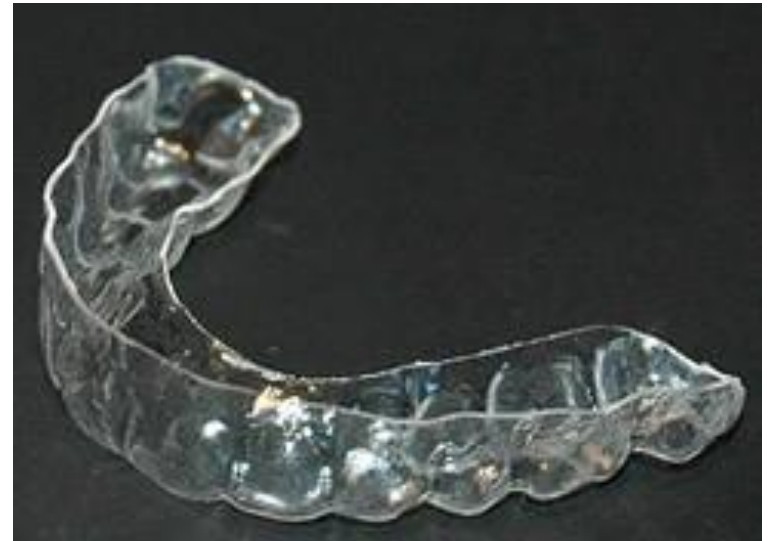dentalnet



## ESSIX

Developed in 1993

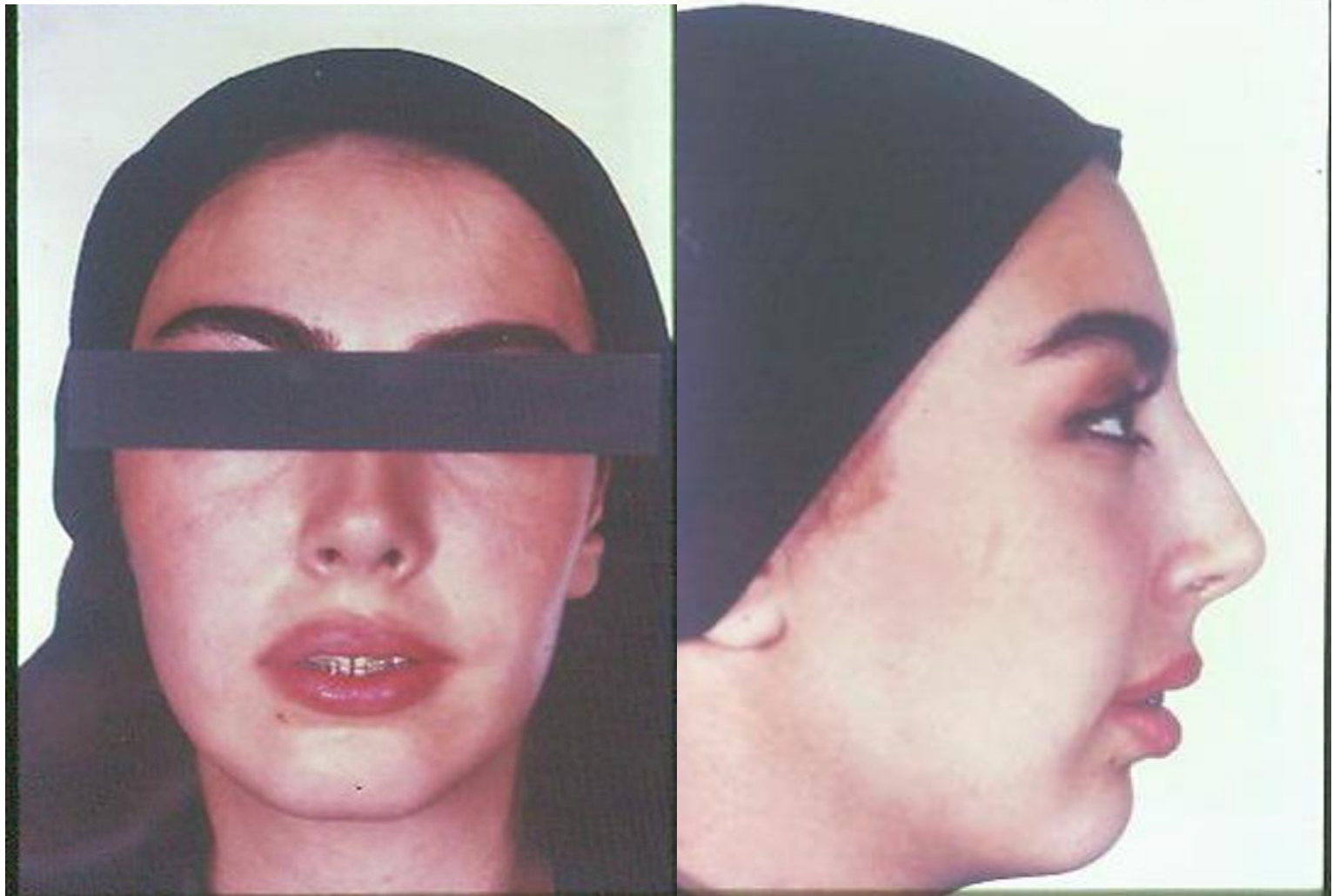- This is a polypropylene or polyvinylchloride (PVC) material, typically .020" or .030" thick.
- Plastic removable appliance



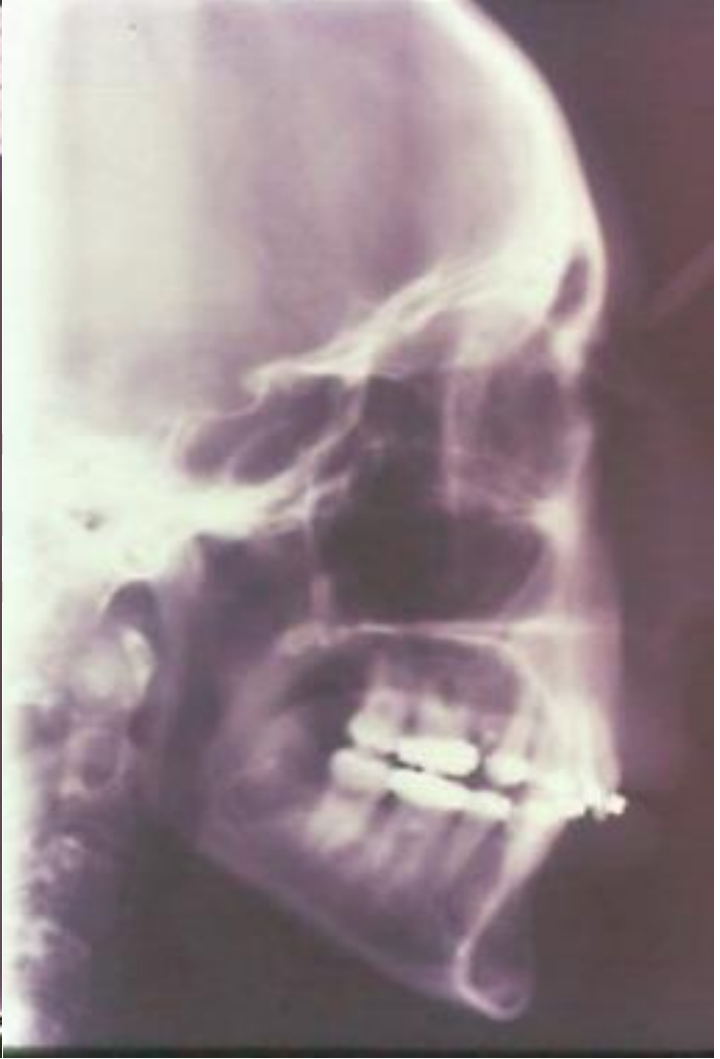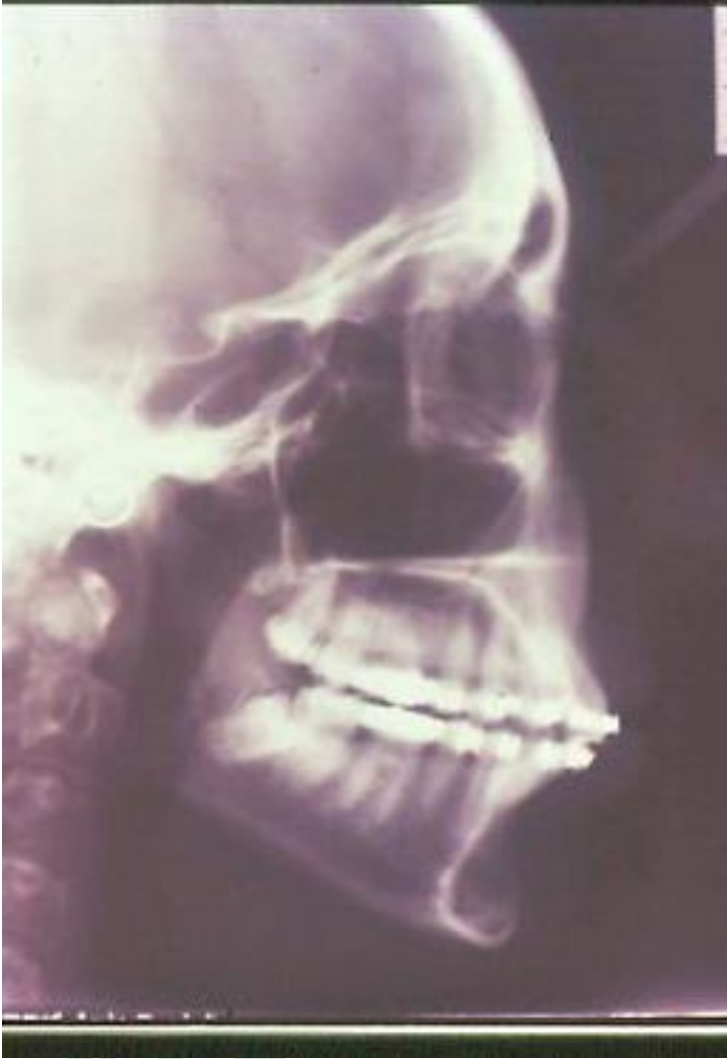## Advantages:

- Esthetic
  - Patient is more likely to wear
  - Inexpensive
  - Quick fabrication
  - Minimal bulk
  - High strength
  - No adjustments
  - Usually does not interfere with speech or function

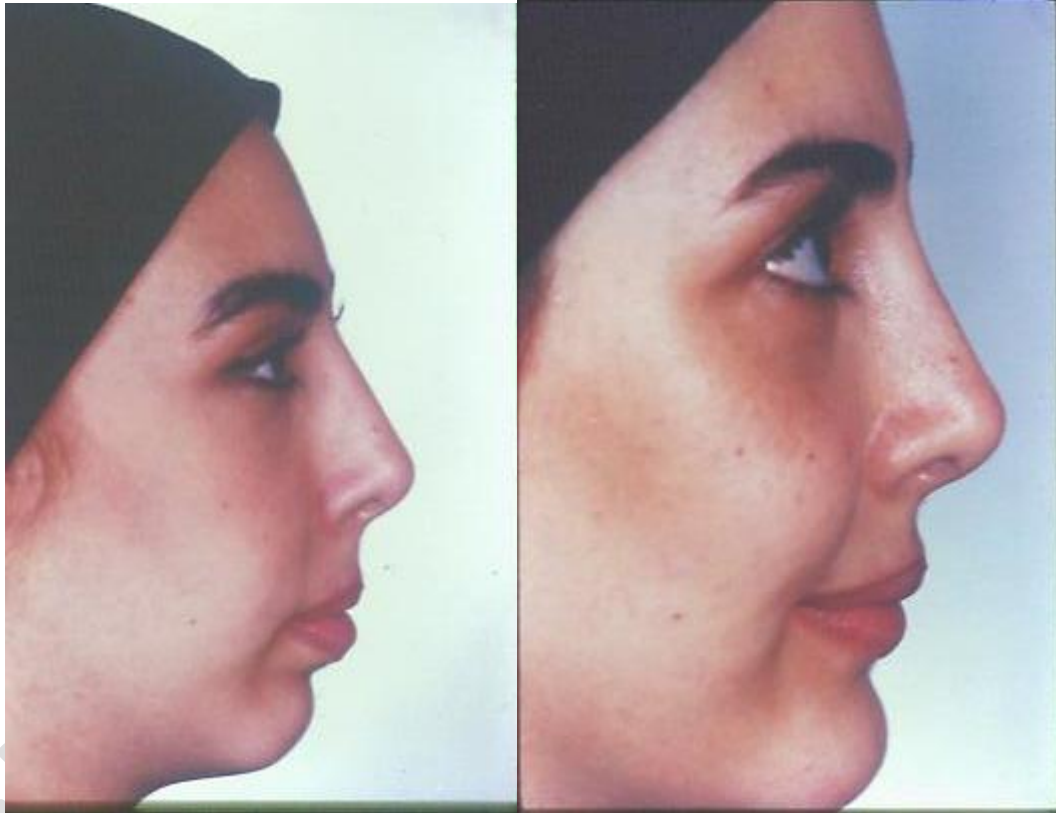x



http



26



<https://jamilian.net>